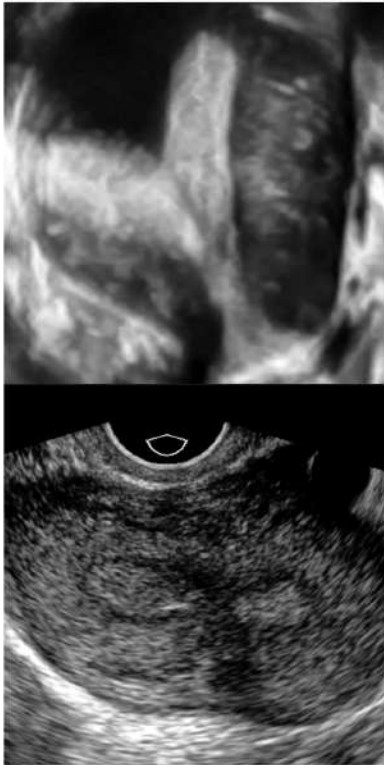


## SUCCESS STORY



### Dr. Rashmi Parikh

Consultant Radiologist  
Imaging Department  
Nanavati Super Speciality Hospital  
Mumbai



Two separate endometrial cavities are identified suggestive of septate uterus

 **Nanavati**  
Super Speciality Hospital  
*a passion for healing...*

## Keeping Hopes Up

A 32-year-old female approached Nanavati Super Speciality Hospital, Mumbai for a routine pelvic ultrasound in view of repeated missed abortions. She is an NRI who had lost hope of bearing a successful pregnancy.

The patient had undergone numerous ultrasound scans which reported normal uterus and ovaries. However, she was unable to continue her pregnancy beyond 6-7 weeks of gestation.

A septate uterus is a deformity of the uterus, which happens during fetal development before birth, which may lead to an increased rate of pregnancy loss. This patient came to the hospital on OPD basis. Scanning her on partially filled urinary bladder suspected Mullerian anomaly as the uterus appeared septate. So, the patient was re-examined on a full bladder which confirmed the findings. Also, 3D pelvic images were obtained for the same. A dedicated pelvic MRI was run for better anatomical evaluation.

A dedicated approach and following correct basic protocols are most important and can help in correct diagnosis which otherwise could be easily missed as in this case.

*"A septate uterus does not typically affect a woman's ability to conceive, but it does significantly increase the risk of a miscarriage."*