

SUCCESS STORY

Food For Thought

Timely intervention saved a man's life using Bronchoscopy

THE CASE

A 72 year old diabetic man on insulin with a history of heart bypass done 3 years ago was admitted with complaints of increasing breathlessness, cough and high fever for past 7 days. He was prescribed antibiotics by his physician but there was no response. On admission, his X-ray chest showed right lower lobe partial collapse with right middle lobe consolidation. WBC counts were 26000 with neutrophilia. Patient was admitted in ICU. Immediately treatment was started. A Bronchoscopy was planned. Considering patient's age, heart status and respiratory distress, it was a high risk procedure.

THE PROCEDURE

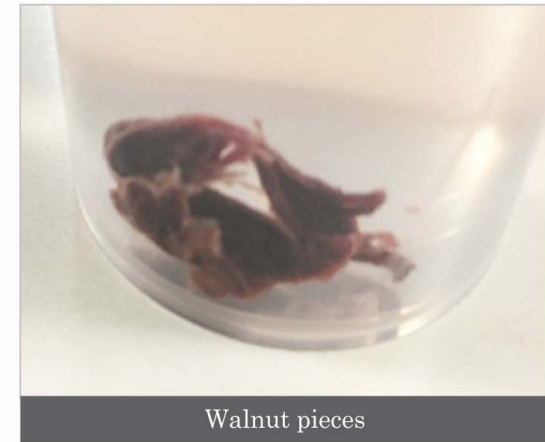
Bronchoscopy revealed right lower lobe bronchus partially blocked with food material. There were thick pus plugs. The foreign material was removed with help of Bronchoscopy forceps and basket. On detailed examination, the food material removed by Bronchoscopy revealed walnut shells. Retrospective history from the relatives proved that 2 days prior to the fever and cough the patient had a severe bout of cough while chewing and swallowing walnuts.

THE RESULT

Post Bronchoscopy the patient showed improvement with complete clearance of the partial obstruction and pus. WBC count came to near normal. The patient was then shifted to ward and was discharged in a week.



Prof. Dr. Salil Bendre
Head - Pulmonary Medicine



Walnut pieces



Nanavati
Super Speciality Hospital
a passion for healing...